



FETAL SURGERY FOR MYELOMENINGOCELE



**Children's Hospital
of Philadelphia®**

Center for Fetal Diagnosis & Treatment

A GUIDE TO SPECIALIZED FETAL MMC SURGICAL REPAIR

Since December 2010, fetal surgery for myelomeningocele (MMC), the most common and severe form of spina bifida, has been offered as a standard of care at Children's Hospital of Philadelphia. This is one of the most exciting developments in the history of treatment for birth defects.

An extremely complex procedure available only to qualified candidates, fetal surgery for MMC requires significant commitment on the part of mothers who choose to go forward with it and extensive surgical experience to perform successfully. Mothers who choose fetal surgery require comprehensive counseling on the condition and the risks involved in the procedure.

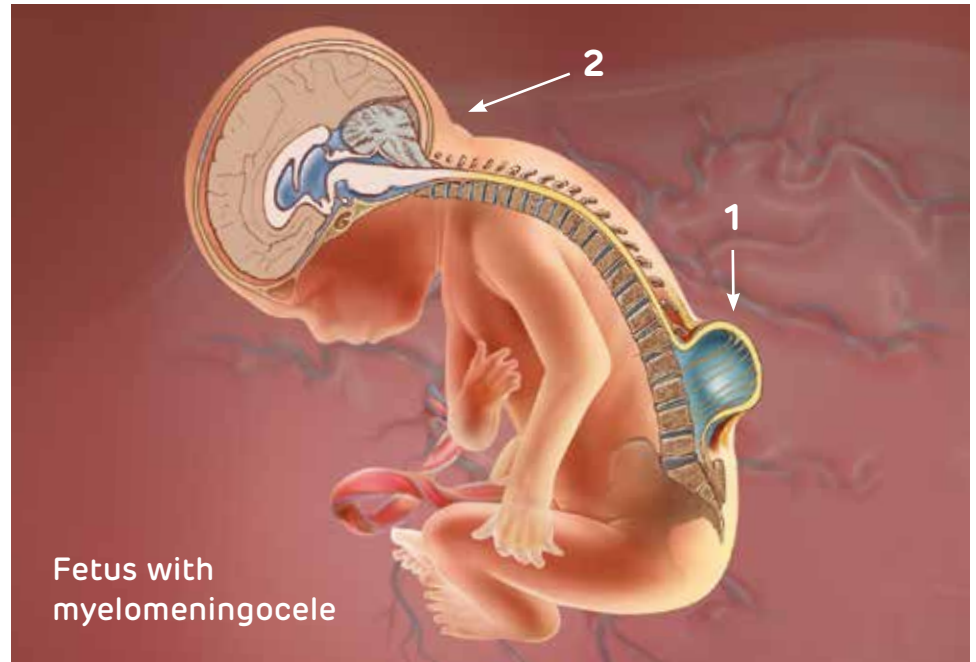
This guide provides an overview of fetal MMC closure, including confirmation of the diagnosis, patient criteria for fetal surgery, the surgical procedure, delivery and follow-up care. We welcome the opportunity to discuss individual candidates for referral.

TYPES OF SPINA BIFIDA

- Myelomeningocele (MMC) ►
- Myeloschisis
- Lipomeningocele
- Myelocystocele

Open neural tube defects such as myelomeningocele and myeloschisis are treatable by fetal closure.

Closed neural tube defects such as lipomeningocele and myelocystocele are not treatable by fetal repair.



Fetus with myelomeningocele

1. Part of the spinal cord and spinal nerves, usually encased in a sac, protrude through an opening in the back and are exposed to the toxic effects of amniotic fluid.
2. Arnold-Chiari II Malformation: Cerebrospinal fluid (CSF) leaks through the opening in the back, and the brain stem (hindbrain) descends, or herniates, into the spinal canal in the neck and blocks the circulation of CSF. This can cause a damaging buildup of fluid in the brain called hydrocephalus.

FACTS ABOUT MYELOMENINGOCELE

- Most common and serious form of spina bifida
- Primary failure of neural tube formation (closure)
- Genetic and micronutrient causes; considered multifactorial in origin
- 1 per 2,000 live births, or 1,500 babies in the U.S. each year
- Increased risk for early death; particularly due to hindbrain herniation
- 80%-85% require shunts, half of which develop complications in first year of life
- 3%-4% recurrence risk in subsequent pregnancies

Long-term Consequences

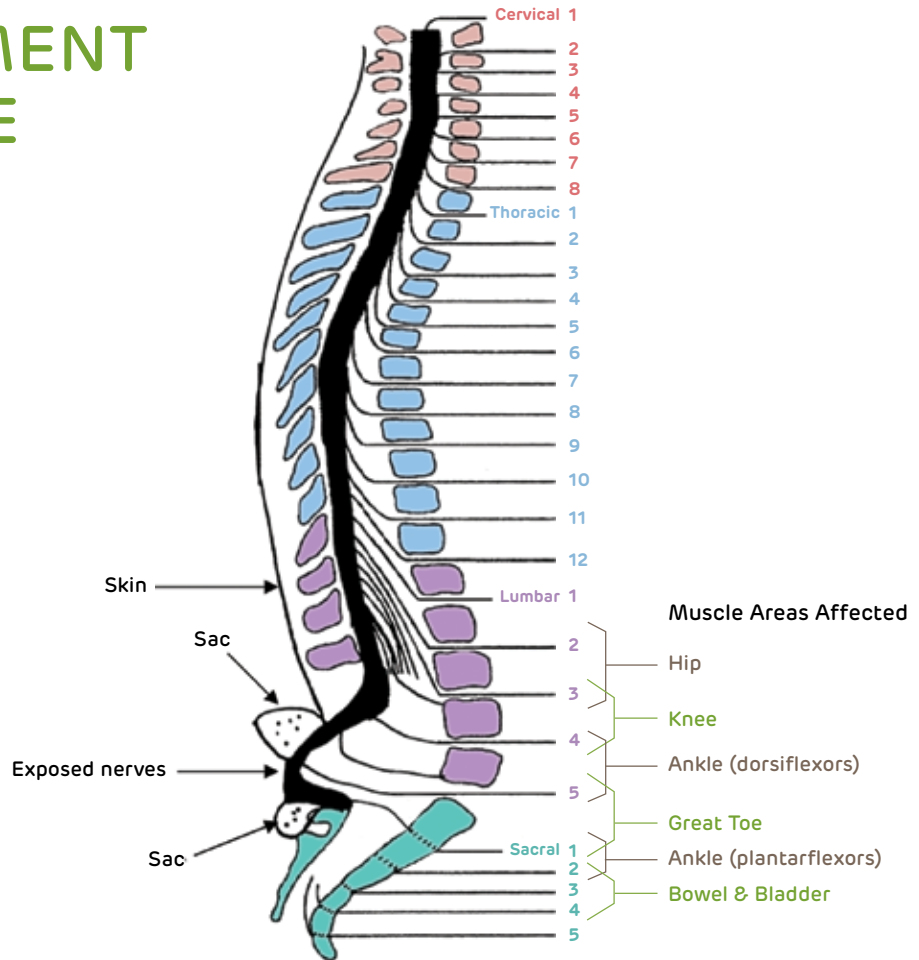
- Hydrocephalus
- Hindbrain herniation complications
- Ventriculoperitoneal shunting
- Paralysis and cognitive impairments
- Orthopaedic malformations (such as club foot)
- Bladder and bowel incontinence
- Sexual dysfunction
- Social and emotional challenges
- Lifelong quality-of-life issues

MOTOR IMPAIRMENT RELATED TO THE LEVEL OF THE DEFECT

MMC can occur at any level in the developing spine, but occurs most often in the lumbosacral region.

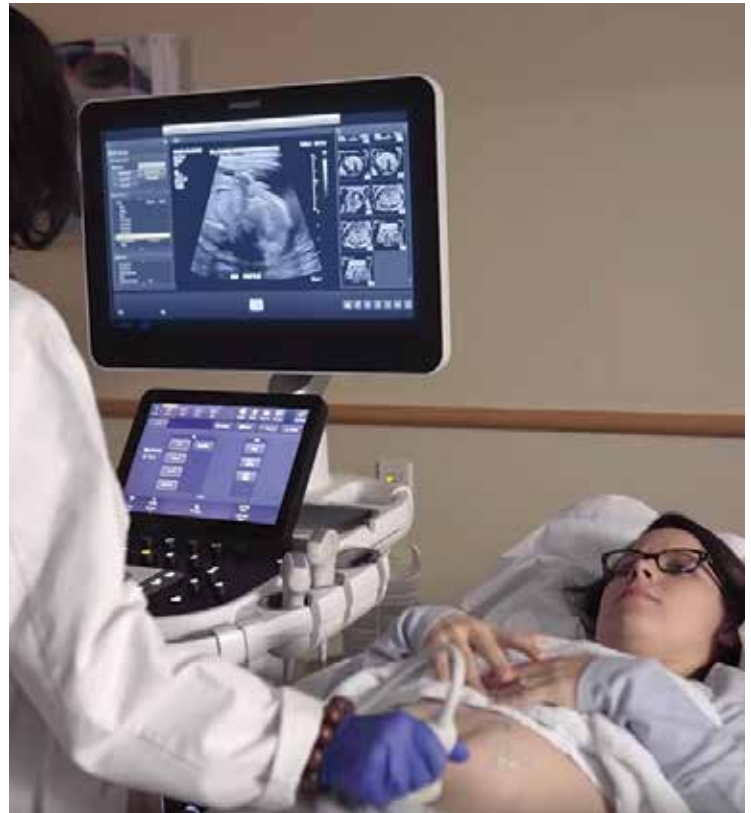The higher the defect on the spine, the more severe the complications.

Areas below the level of the defect will be affected. This illustration shows a defect at the L 4-5 level.



MAKING THE DIAGNOSIS

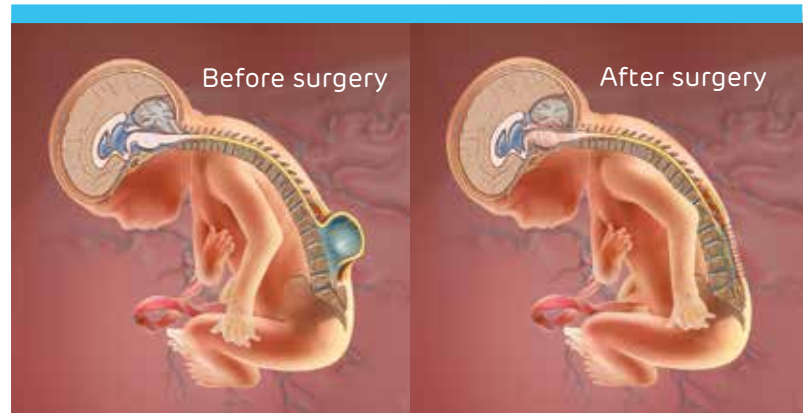
- **Maternal serum alpha-fetoprotein (MSAFP)** test. Abnormally high AFP levels can suggest a neural tube defect.
- **Level II ultrasound** to confirm spinal defect, determine level of lesion, confirm features in the brain that indicate spina bifida and assess deformities such as talipes (club foot).
- **Amniocentesis** to confirm presence of elevated amniotic fluid alpha-fetoprotein (AFAFP) levels and acetylcholinesterase (AChE), which indicates open (vs. closed) neural tube defect. Amniocentesis is required to be considered for fetal surgery and microarray analysis is preferred. You will receive counseling about these results.



RATIONALE FOR FETAL MMC SURGERY

Results of Management of Myelomeningocele Study (MOMS)* showing outcomes after prenatal closure vs. postnatal closure:

- Reduced need for ventricular shunting at 12 months of age (40% of prenatal surgery group, compared to 82% of postnatal surgery group)
- Reduced incidence or severity of neurologic effects, e.g., impaired motor and sensory function of legs
- Improved ambulation at 30 months of age
- Reversal of hindbrain herniation component of Arnold-Chiari II malformation



Spinal cord damage is progressive during gestation. A watertight fetal MMC surgery may prevent further damage caused by amniotic fluid exposure and reverse the hindbrain herniation feature of the Arnold-Chiari II malformation by stopping the CSF leak.

*Adzick NS, et al. "A Randomized Trial of Prenatal versus Postnatal Repair of Myelomeningocele." *N Engl J Med.* 2011;364(11):993-1004.

FETAL SURGERY OUTCOMES AT CHOP SINCE THE MOMS TRIAL

OUTCOMES WITH FETAL SURGERY FOR MMC AT CHILDREN'S HOSPITAL OF PHILADELPHIA ARE THE SAME OR BETTER THAN THOSE REPORTED IN THE MOMS TRIAL.

Given all of our team's experience, we have improved upon all outcomes reported by the MOMS trial.

Key outcomes and measures of success:

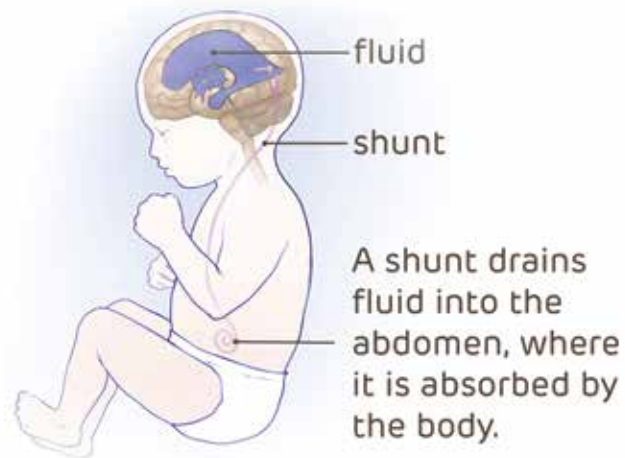- CHOP's rate of transfusion (1.25%) is lower than the MOMS trial (9%) at the time of cesarean delivery due to the continuity of care and experience of the delivery team members.
- Rates of preterm labor and membrane separation were lower for the CHOP cohort vs. the MOMS trial.
- At CHOP, more than 60% of babies that undergo fetal surgery deliver at or after 37 weeks, similar to the MOMS trial gestational age at delivery.

continued >

FETAL SURGERY OUTCOMES AT CHOP SINCE THE MOMS TRIAL

< continued

- CHOP had a lower rate of PPROM of 32.3% compared to the MOMS trial cohort of 46.2%.
- On neonatal MRI, hindbrain herniation was reversed in more than 90% of our fetal surgery patients.
- The average birth weight was comparable to the MOMS trial.
- The rate of hydrocephalus therapy with a shunt or endoscopic third ventriculostomy (ETV) procedure at 12 months of age is 34%.
- A follow-up program is in place for improving long-term outcomes.



WHEN IS FETAL SURGERY FOR MMC AN OPTION?

Partial list of inclusion criteria:

- Singleton pregnancy
- Maternal BMI \leq 40
- Confirmed presence of elevated AFAFP and AChE
- Confirmed normal genetic testing
- Absence of associated fetal anomalies
- Myelomeningocele at level T1 through S1
- Arnold-Chiari II malformation (hindbrain herniation)
- Gestational age at time of fetal surgery is between 23 weeks, 0 days to \leq 25 weeks, 6 days
- Maternal age \geq 18 years

To see an extensive list of inclusion and exclusion criteria for fetal MMC repair at CHOP, visit fetalsurgery.chop.edu/spinabifida or call 1-800-IN UTERO (468-8376).

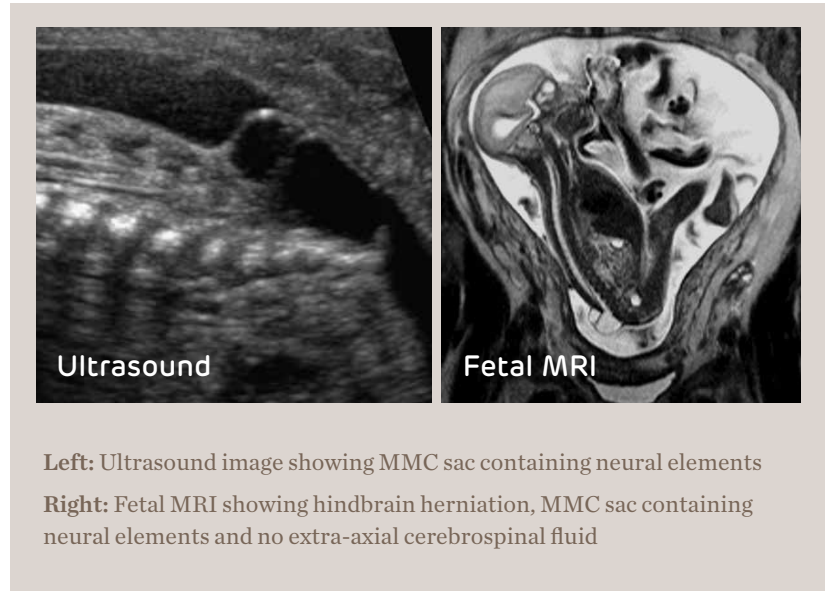
EVALUATION AT THE CENTER FOR FETAL DIAGNOSIS AND TREATMENT

A COMPREHENSIVE MULTIDISCIPLINARY EVALUATION

Diagnostic testing includes:

- **High-resolution level II ultrasound** to confirm location of MMC and assess for other birth defects
- **Ultrafast fetal MRI** to confirm presence of the hindbrain herniation components of Arnold-Chiari II malformation and screen for evidence of other brain or spinal abnormalities and any other structural defects not related to MMC
- **Fetal echocardiogram** to evaluate heart structure and function

continued >



EVALUATION AT THE CENTER FOR FETAL DIAGNOSIS AND TREATMENT

< continued

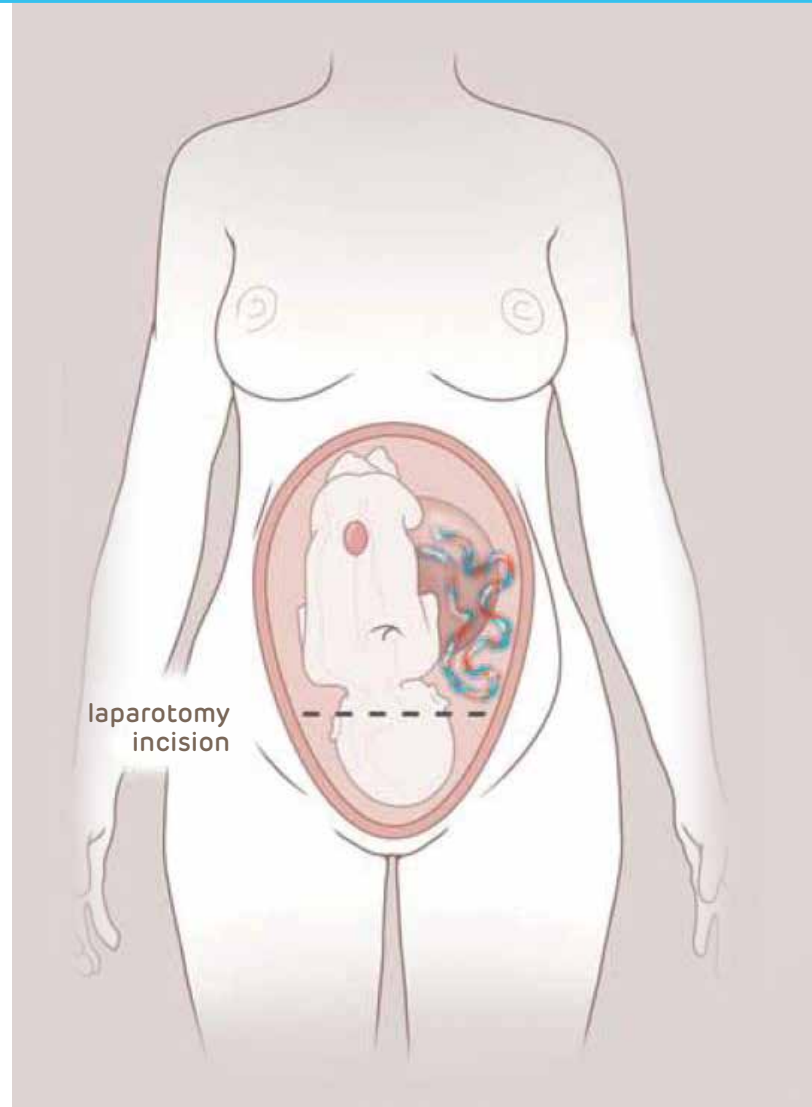
Patient counseling and education includes:

- **Review of spina bifida** and associated medical problems, and prenatal and postnatal options with high-risk obstetrician and neurosurgeon
- **Physical exam** of mother, review of medical history, and clearance for surgery by anesthesiologist and high-risk obstetrician
- **Review of pre- and postnatal care** and monitoring
- **Neonatology counseling** about possible preterm birth
- **Review of medications** necessary before, during and after prenatal surgery
- **Social work psychosocial evaluation** to assess readiness for surgery, coping mechanisms and family support
- **Review of surgical procedure** (if opting for fetal surgery) and its risks with fetal surgeon. Risks include uterine scarring, membrane separation, infection, bleeding, prematurity and fetal demise.

FETAL MMC SURGERY

- Mother and fetus receive general anesthesia. The fetus also receives a shot.
- Fetal surgeon performs laparotomy and the uterus is opened with a uterine stapling device that pinches off all blood vessels and keeps the membranes tacked up to the muscle layer of the uterus
- Sterile intraoperative ultrasound is performed by a maternal-fetal medicine specialist
- Fetus' back is rotated into view

continued >



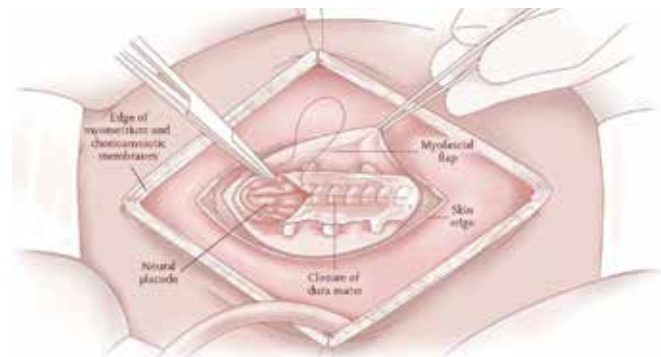
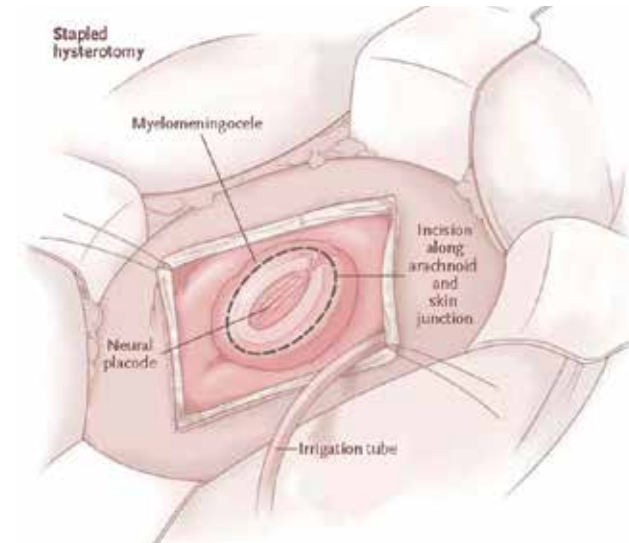
FETAL MMC SURGERY

< continued

- Fetal cardiologist performs continuous fetal heart monitoring by echocardiography
- Pediatric neurosurgeon resects the MMC sac from the exposed spinal cord (neural placode) and skin edges, returns the cord to the spinal canal, and closes the surrounding tissue and skin over the defect in a watertight manner
- Uterine and abdominal incisions are closed in multiple layers

Adzick NS, et al. "A Randomized Trial of Prenatal versus Postnatal Repair of Myelomeningocele," *N Engl J Med*. 2011 Mar 17;364(11):993-1004. Epub 2011 Feb 9.

Heuer GG, Adzick NS, Sutton LN. "Fetal Myelomeningocele Closure: Technical Considerations." *Fetal Diagn Ther*. 2015;37(3):166-171.



FROM FETAL CLOSURE TO DELIVERY

- Mother remains in the hospital 3–5 days if there are no complications
- She remains on modified bed rest for 3–4 weeks; restricted activity until delivery
- Weekly ultrasound monitoring and prenatal care visits
- Goal is planned cesarean delivery at 37 weeks
- Postnatal care in the Newborn/Infant Intensive Care Unit (N/IICU) using our standardized patient care protocols



WHAT TO EXPECT IN THE N/IICU

Upon admission, multidisciplinary consult with:

- Neurosurgery
 - Urology
 - Orthopaedics
 - Physical Therapy
 - Spina Bifida Clinic
- Head ultrasounds
 - MRI of brain and spine
 - Daily head circumference
 - Renal and bladder ultrasound on day of life 2
 - Bladder scans with a handheld ultrasound device every 4 hours for the first 48 hours to estimate the amount of urine in the bladder and whether the baby requires catheterization
 - Clean intermittent catheterization if the bladder volume is greater than 50% of expected volume
 - Video urodynamics study at 2 to 3 months of age
 - Urinary tract infection prophylaxis
 - Evaluation for possible shunt

FOLLOW-UP

- Patients receiving follow-up care through CHOP are seen in our Spina Bifida Clinic, the nation's first program to bring a multidisciplinary approach to long-term follow-up for spina bifida. Patients not receiving follow-up care through our hospital will undergo follow-up at a spina bifida clinic near their home. The clinic must include experts from pediatrics, nursing, neurosurgery, orthopaedics, urology, physical therapy, social work and genetics.
- Follow-up includes visits every few months for the first year of life, every six months from age 1 to 5, then annually, with urodynamic testing and renal bladder ultrasounds to ensure kidneys function properly and bladder function is stable.
- Depending upon location of lesion and outcome after surgery, follow-up may also include: Clean intermittent catheterization; bowel management; lower extremity bracing; physical therapy evaluation and guidance to outside physical therapists and early intervention; pressure sore management; referral to appropriate psychosocial and financial resources; consultation with other subspecialties including ophthalmology, nephrology, nutrition and feeding team, and plastic surgery.

OUR CENTER IS
COMMITTED TO THE
COMPREHENSIVE
LONG-TERM FOLLOW-UP
OF OUR PATIENTS TO
PROVIDE THE BEST CARE
FOR CHILDREN AND
THEIR FAMILIES, AND TO
CONTINUOUSLY GAINING
NEW KNOWLEDGE SO WE
CAN ADVANCE CARE FOR
FUTURE GENERATIONS.

CHOP EXPERIENCE IN FETAL MMC REPAIR

Suspected prenatal diagnosis of
MMC since September 1995:

Patient referrals

OVER
2,525

Patient evaluations

OVER
1,395

Fetal surgeries

OVER
360

SDU deliveries

OVER
425

*About 1 in every 3 patients we evaluate
is a candidate for fetal repair.*

Center for Fetal Diagnosis and Treatment at CHOP, data on file as of 6/2019

WE HAVE AN UNPARALLELED LEVEL OF CONTINUOUS EXPERIENCE:

- Leaders in development and research of fetal MMC repair for over 30 years
- First fetal MMC repair performed in 1998
- Performed 58 fetal MMC repairs, meeting strict inclusion criteria, before start of MOMS trial
- More than 1,795 fetal surgeries (all diagnoses) for patients from all 50 states and more than 70 countries

Adzick NS, et al. "Successful Fetal Surgery for Spina Bifida." *Lancet*. 1998;352(9141):1675-1676.

KEY RESOURCES

CHILDREN'S HOSPITAL OF PHILADELPHIA

Center for Fetal Diagnosis and Treatment
fetalsurgery.chop.edu/spinabifida
1-800-IN UTERO (468-8376)

Spina Bifida Clinic
215-590-2483

SPINA BIFIDA ASSOCIATION

spinabifidaassociation.org

CENTERS FOR DISEASE CONTROL AND PREVENTION

cdc.gov/ncbddd/spinabifida

SPINA BIFIDA CONNECTION

spinabifidaconnection.com

MARCH OF DIMES

marchofdimes.com

CONTACT US

1-800-IN UTERO (468-8376)
or 215-590-5190

fetalsurgery.chop.edu



**Children's Hospital
of Philadelphia®**

Center for Fetal Diagnosis
& Treatment

©2019 Children's Hospital of Philadelphia. 19CFDT0308/1000/9-19